

COMMENT AND OPINION

A titanium plug simplifies left ventricular assist device removal after myocardial recovery

To the Editor:

Myocardial recovery in patients with dilative cardiomyopathy occurs in 5% to 10% after implantation of left ventricular assist devices (LVADs). Recovery also occurs in patients with ischemic cardiomyopathy, but in a smaller proportion. The standard explantation technique requires mobilization of the device through a median sternotomy or by a left subcostal approach and preparation of the apex, removal of the sewing ring, and closure of the hole in the myocardium of the apex (approximately 1.5–2 cm in diameter) by plication using Teflon (DuPont, Wilmington, DE) strips. This technique leads to loss of some viable myocardium and to distortion of the LV geometry. We describe the use of an individually designed and manufactured titanium plug for the explantation of HeartMate II LVADs (Thoratec, Pleasanton, CA) without any manipulation of the LV apex.

The plug was manufactured by Steffan Fittkau GmbH (Berlin, Germany) using a titanium alloy and a titanium microsphere sintering, both similar to the materials of which the inflow cannula of the pump itself is made. The top and outside walls of the plug, except the lip, were sintered to ensure that all blood contact surfaces are covered with microspheres. The diameter of the plug was exactly the same as that of the inflow cannula of the HeartMate II. The lip on the top of the plug was created to prevent the plug from being inserted too far and for fixation (through 6 additional small holes) by sutures to the sewing ring. The length of the introducer portion of the plug was constructed to be 8 mm longer than the cuff of the sewing ring, so that it reaches the level of the endocardium but does not protrude into the LV. The plug is hollow to reduce its weight. The holes enable use of the special plug holder, which facilitates plug positioning during surgery (Figure 1). The plug attached to the holder is visible in Figure 1 ready for insertion.

We used this technique in 4 patients (2 men and 2 women) aged between 45 and 63 years, for explantation of the HeartMate II LVAD after 192, 277, 316 and 324 days of support, respectively. After cardiopulmonary bypass was instituted through the femoral vessels, redo median sternotomy was performed. Pre-operative computed tomography and transesophageal echocardiography showed no thrombus formation around the inflow cannula. The drive line to the pump was cut with heavy wire cutters, and the heart and the pump with inflow and outflow grafts were separated from adhesions. The sutures securing the pump inlet cannula to

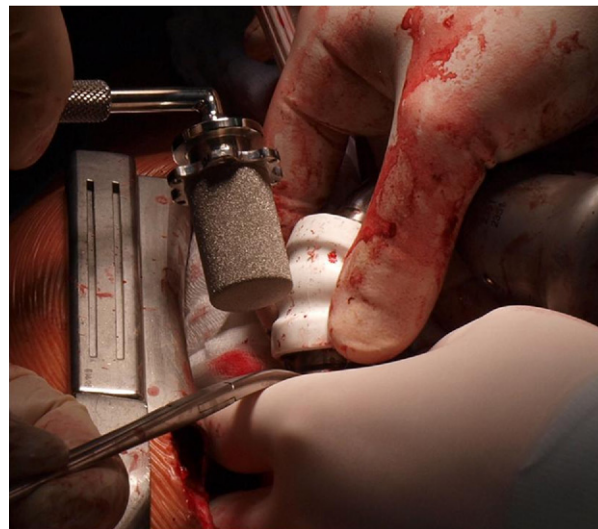


Figure 1 Intraoperative view shows the plug and plug holder ready for insertion, immediately before removal of the inflow cannula of the HeartMate II.

the sewing ring on the left ventricular apex were cut, and the pump inlet was removed with the patient positioned head down. The pump was passed off the field. After flush-out (2 to 3 heart beats) through the apex opening, the cavum was examined for thrombi or other particles, and the titanium plug was inserted and secured by sutures after adequate deairing (Figure 2).

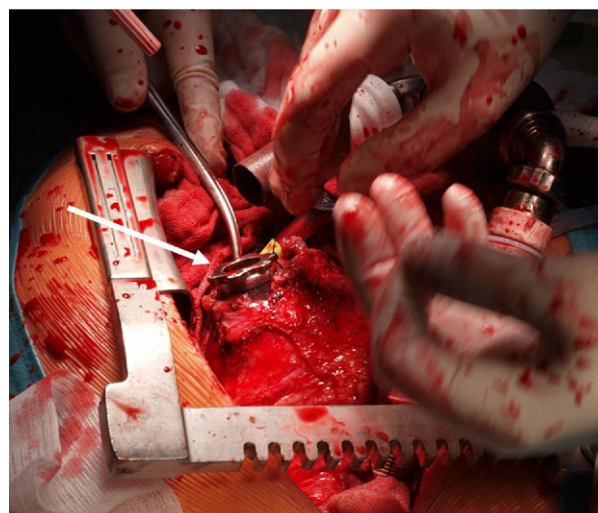


Figure 2 Intraoperative view shows the operative field after the HeartMate II inflow cannula was removed and the plug inserted and secured.

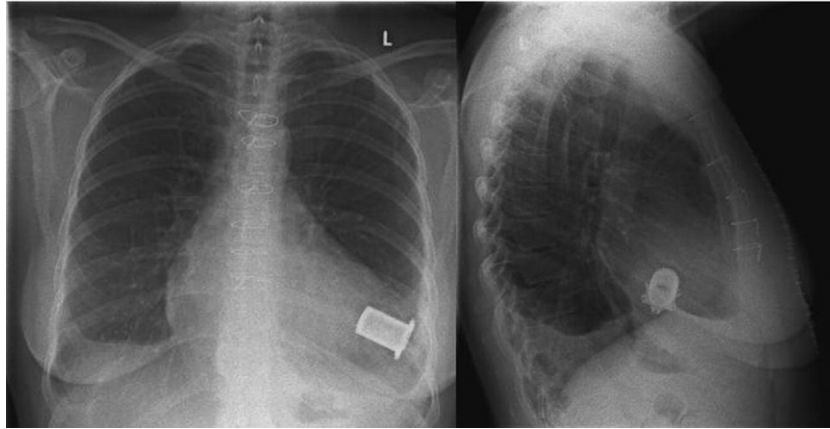


Figure 3 Postoperative X-ray with the plug in situ.

After meticulous hemostasis, the patients were weaned from cardiopulmonary bypass, and the chest was closed in the usual fashion. The patients had uneventful post-operative courses without bleeding or reexploration. After 3 months of vitamin K antagonist treatment, the patients received 100 mg of aspirin daily. No thromboembolic events occurred during outpatient follow-up of 10 months. Echocardiographic studies showed no thrombus formation in the LV, no pericardial effusion or false aneurysm, and normal motion and geometry of the apex of the LV.

Myocardial recovery after long-term VAD support is a reality and should be taken into consideration in patients with myocarditis or dilative cardiomyopathy, as well as in patients with VAD inserted for post-cardiotomy heart failure or acute myocardial infarction. Several reports from our group¹ and others² show that significant numbers of patients may be successfully weaned from LVAD with subsequent LVAD explantation with good quality of life.³ The number may also be increased by using adjuvant drugs. Explantation of these devices is a challenging procedure.² The usual technique, with plication of the myocardium around the apex, requires complete dissection of the adhesions surrounding this area and inevitably leads to some loss of viable myocardium and changes in LV geometry.

Cohn described a handmade felt plug fashioned in the operating room and inserted into the sewing ring of the HeartMate II LVAD.² The creation of the felt plug in the operating room is time consuming, its fixation is not optimal, and thrombi may form on the felt surface. Further, the felt does not hermetically close the hole, and pericardial effusion or false aneurysm may be a consequence.

Tightening of the titanium plug with ligatures enables hermetic closure, and additional fixation through special holes precludes its dislocation in any direction. The special plug holder enables easy, safe, and quick placement and fixation of the plug in the sewing ring. The titanium plug covered with titanium microspheres will be covered with neointima and subsequently presents low risk for thrombus formation on the surface of the plug, as described for HeartMate I, where the blood contact surface is covered with a similar technique. The plug would enable safe off-pump explantation of the LVAD.⁴ Some potential risk of infection in

connection with the foreign body retained in the circulation (Figure 3) remains, however, and patients should receive prophylactic antibiotic treatment as recommended for patients with mechanical valves.

In conclusion, use of an individually manufactured titanium plug to close the opening of the apex after LVAD explantation through median sternotomy or subcostal approach is a safe procedure, simplifying and shortening surgery, reducing or even eliminating the bypass time, and preserving viable myocardium and the geometry and function of the LV.

Disclosure statement

The authors thank Ms A. Gale for editorial assistance.

None of the authors has a financial relationship with a commercial entity that has an interest in the subject of the presented manuscript or other conflicts of interest to disclose.

Evgenij V. Potapov, MD, PhD
Alexander Stepanenko, MD
Ewald Hennig, PhD
Roland Hetzer, MD, PhD
Thomas Krabatsch, MD, PhD

*Deutsches Herzzentrum Berlin
Berlin, Germany*

References

1. Dandel M, Weng Y, Siniawski H, et al. Prediction of cardiac stability after weaning from left ventricular assist devices in patients with idiopathic dilated cardiomyopathy. *Circulation* 2008;118(14 Suppl):S94-105.
2. Cohn WE, Gregoric ID, Radovancevic B, Frazier OH. A felt plug simplifies left ventricular assist device removal after successful bridge to recovery. *J Heart Lung Transplant* 2007;26:1209-11.
3. George RS, Yacoub MH, Bowles CT, et al. Quality of life after removal of left ventricular assist device for myocardial recovery. *J Heart Lung Transplant* 2008;27:165-72.
4. Cheung A, Bashir J, Kaan A, Kealy J, Moss R, Shayan H. Minimally invasive, off-pump explant of a continuous-flow left ventricular assist device. *J Heart Lung Transplant* 2010 [E-pub: doi:10.1016/j.healun.2010.01.006].